

## 1. Introduction

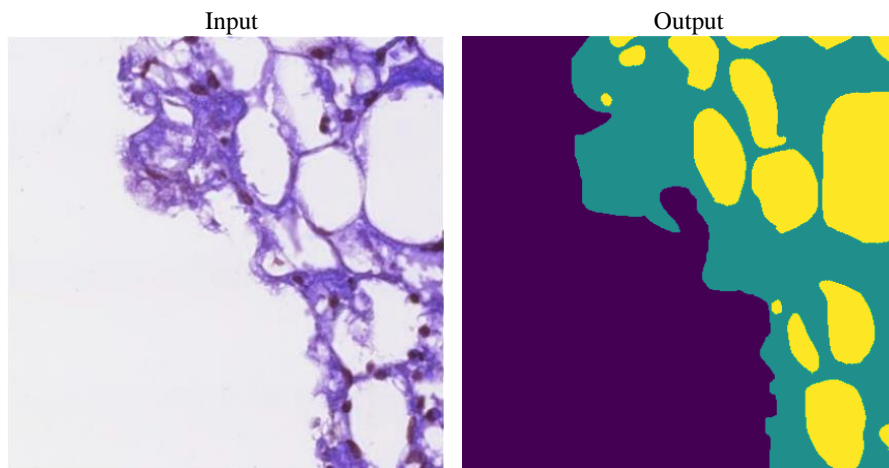
Fatty liver disease or also known as hepatic steatosis is defined by the accumulation of fat in the liver, accounting for at least 5% of the organ's total weight [21]. Severe hepatic steatosis can progress to the point where a liver transplant becomes necessary if it is not treated carefully [34]. One common type of hepatic steatosis is Non-Alcoholic Fatty Liver Disease (NAFLD) and it is estimated to affect 38% of the global population worldwide [37]. Medical experts use liver tissue sample to analyze a patient's liver condition. The collection of liver tissue samples from a patient can be obtained through a liver biopsy procedure.

Whole slide imaging device is often used to produce histopathological image of a liver tissue sample. Histopathological image is a microscopic image of an organ tissue and is used to analyze various diseases, including hepatic steatosis [15]. Steatosis droplets and liver tissue region are two important factor in determining the condition of liver tissue.

Semantic segmentation is the task of segmenting certain areas of an image by labelling each individual pixel in the image to its corresponding class [31]. In the context of hepatic steatosis, semantic segmentation is often focused towards segmenting the steatosis part in an image. When using histopathological image, the segmentation of the steatosis is commonly done at individual droplets because it gives better accuracy when measuring the condition of liver tissue sample. For instance, in Fig. 1, an input image representing a histopathological image sample containing steatosis, tissue, and background is provided. The input image is processed to produce a segmentation output that distinguishes between steatosis, tissue, and background. The segmented image of steatosis and tissue can be utilized to calculate the percentage of fat presence in the liver tissue sample.

At first, hepatic steatosis was analyzed through non-invasive techniques, with ultrasonography being one example. Despite that, the information is not sufficient enough to quantify steatosis percentage, thus histopathological image are used, as they provide better details. Previously, traditional thresholding methods were used for segmenting individual steatosis droplets in a histopathological image which resulted in many segmentation errors. However, with the emergence of U-Net, many experts started adopting it for automatic steatosis segmentation [26, 25]. Nonetheless, existing deep learning models still suffers from accurate steatosis droplets segmentation, especially in a histopathological image with low steatosis occurrences and very small steatosis droplets. Deep learning models also often require a substantial parameters to achieve accurate segmentation of steatosis droplets. Therefore there is still a need for a more lightweight deep learning model which can do segmentation of steatosis droplets accurately.

The aim of this study is to develop a method to segment hepatic steatosis in histopathological images using a more lightweight deep learning architecture, designed to accurately segment individual steatosis droplets. Furthermore, image processing techniques which consist of pre-processing and post-processing were also introduced to improve the segmentation of very small steatosis droplets. The results of this study were evaluated using Intersection over Union (IoU) and mean IoU.



**Fig. 1.** An example of histopathological liver tissue images and their segmentation results. The left image illustrates the input, while the right image is the segmentation result. The 'background' class is highlighted in **purple**, the 'tissue' class in **green**, and the 'steatosis' class in **yellow**.